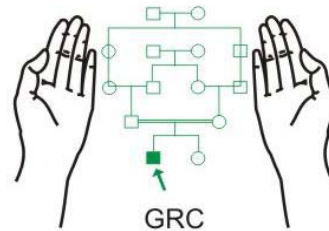


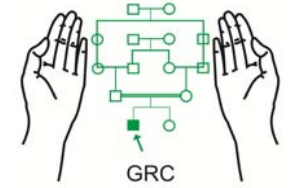
Chorionic Villus Sampling (CVS)

Maj Gen (R) Suhaib Ahmed, HI (M)
MBBS; MCPS; FCPS (Pak); PhD (London)

Genetics Resource Centre (GRC)
Rawalpindi



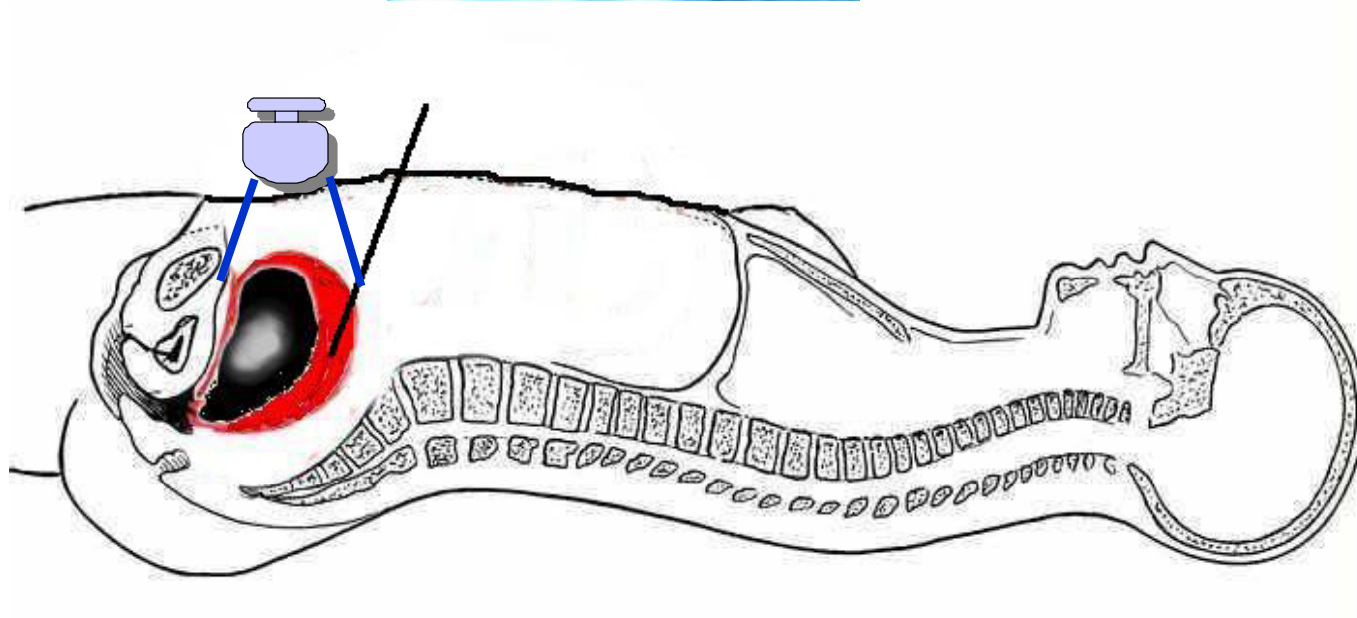
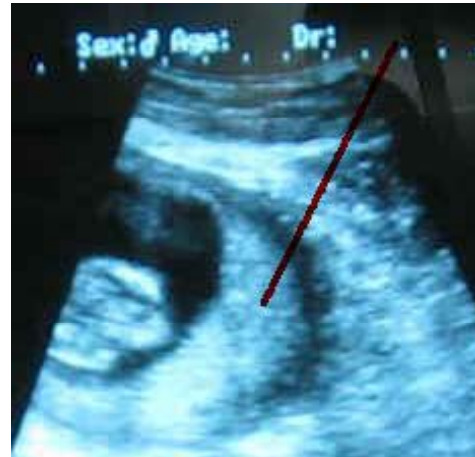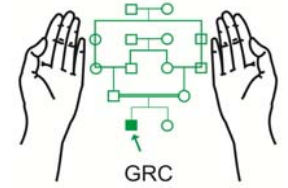
www.grcpk.com



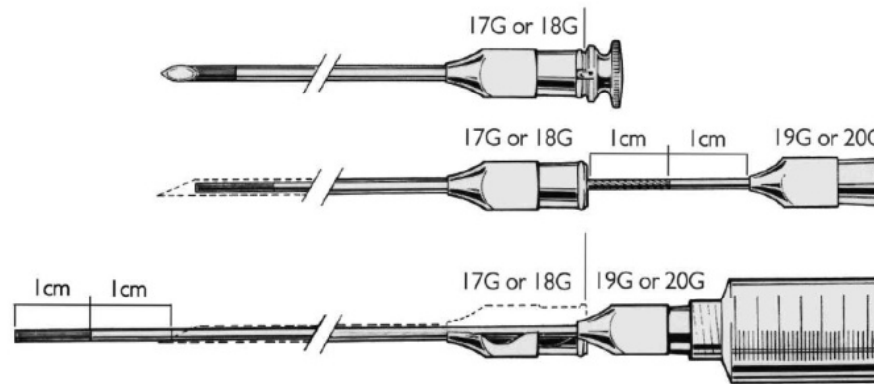
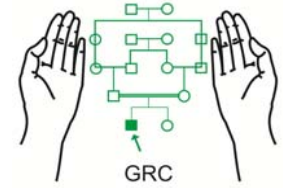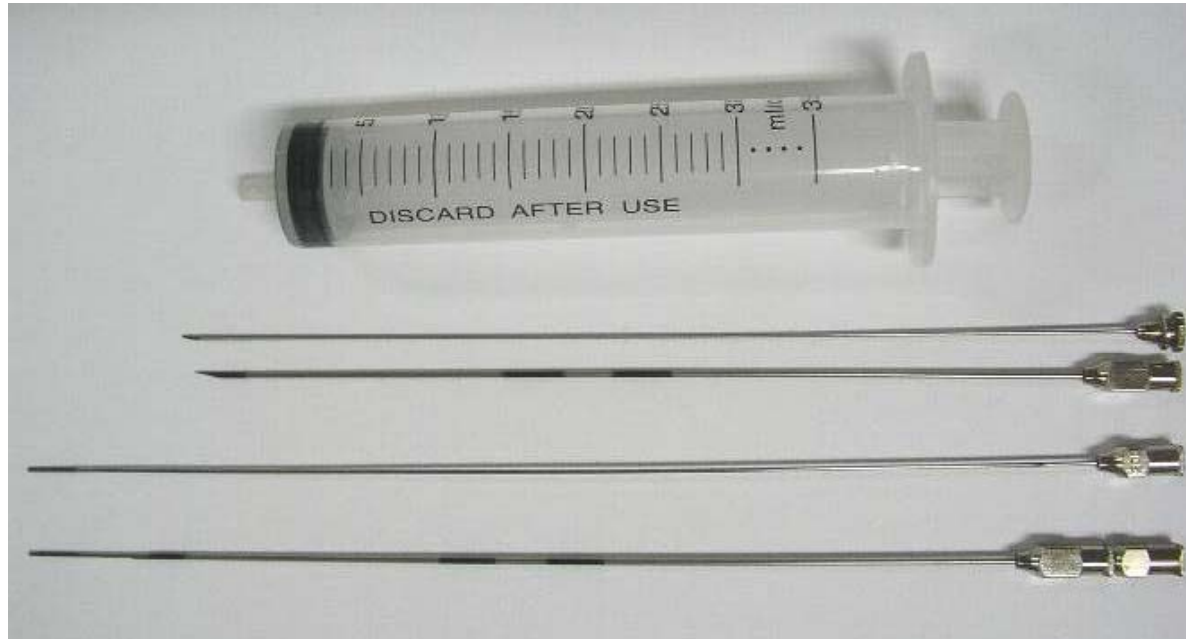
Hippocratic Oath

- I will apply dietetic measures for the benefit of the sick according to my ability and judgment; I will keep them from harm and injustice.

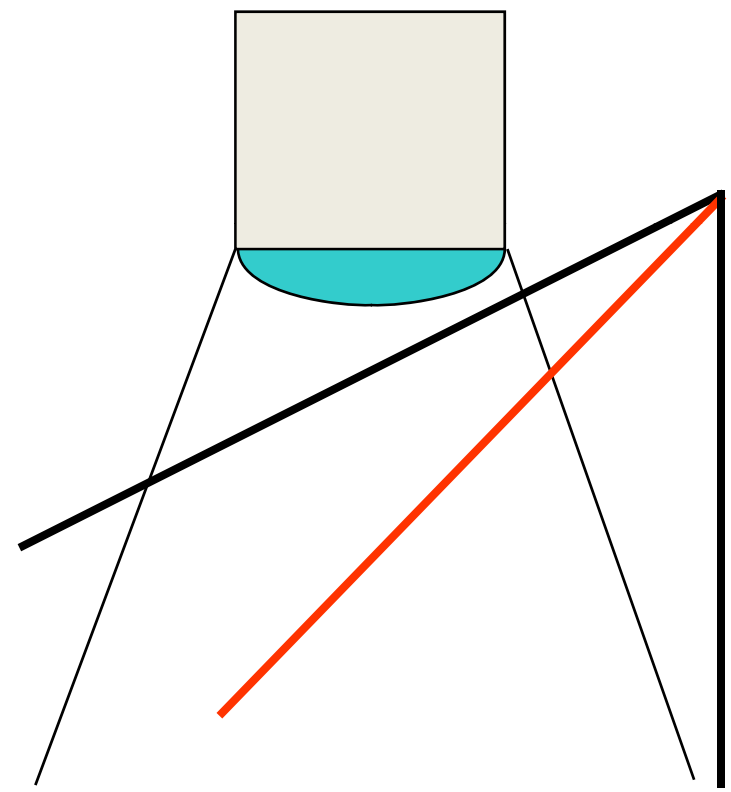
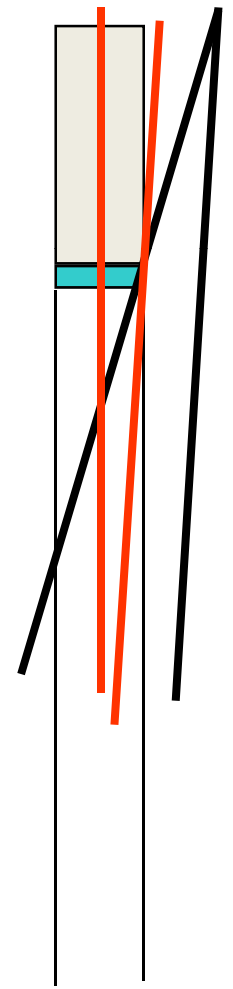
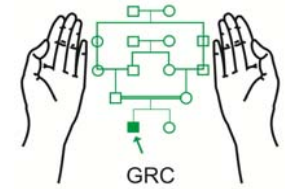
Ultrasound Probe and the Image



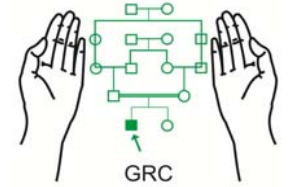
CVS Needle



Probe-needle alignment rules

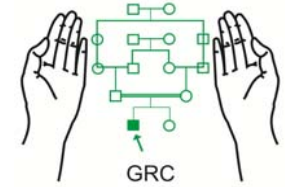


Sampling

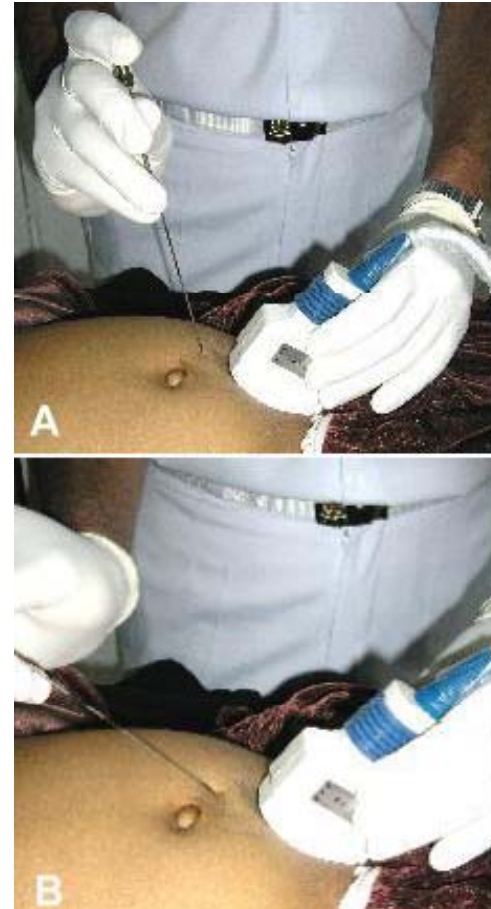


- No special preparation is required
- 3.5 MHz convex probe
- Choose the right spot for entry
- Anterior placenta:
 - Keep the bladder full
- Posterior placenta:
 - Empty bladder may be helpful
 - Sampling may be delayed till 13 or 14 weeks
- Avoid:
 - Peritoneal cavity
 - Amniotic cavity
 - Intestinal loops

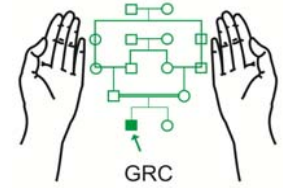
Sampling



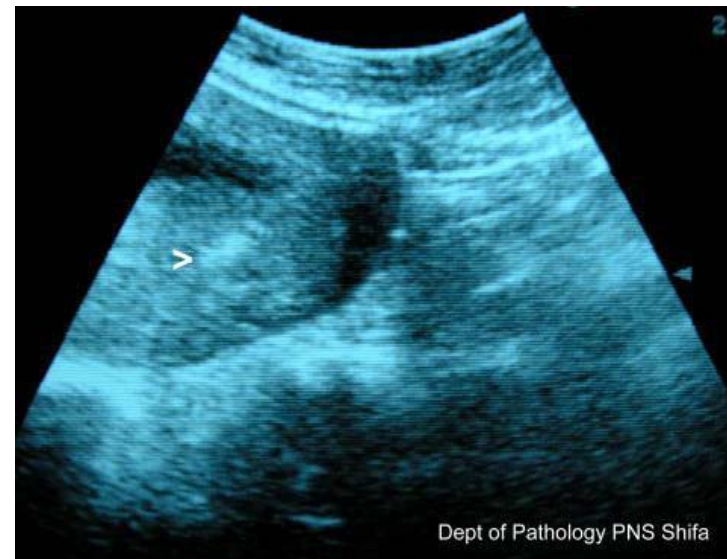- Stand on the left side of the patient
- USG probe in left hand and CVS needle in the right hand
- Skin and serosa are most sensitive



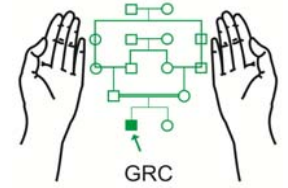
Sampling



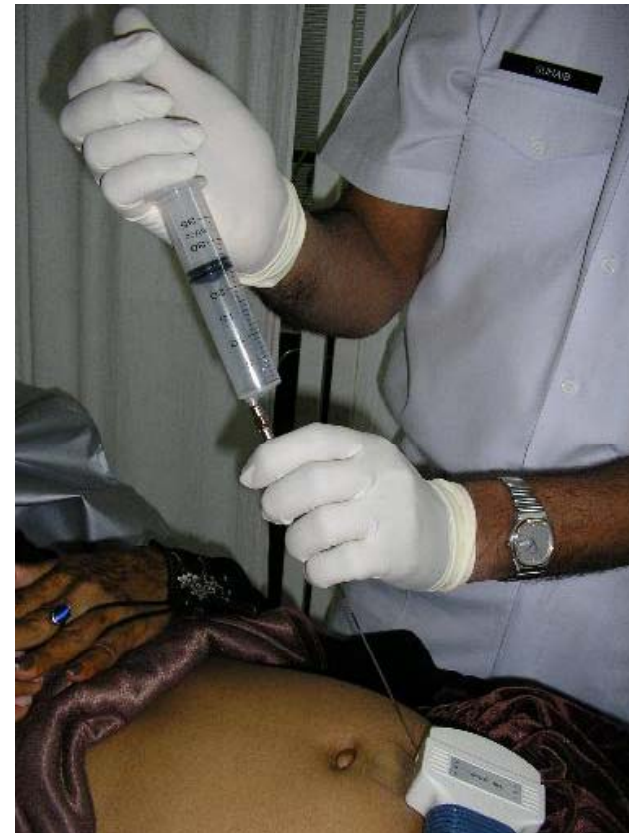- Needle tip should remain visible at all times
- Enter placenta with a jerky push in its longitudinal plane
- It prevents placental separation
- Entry into placenta feels like “hot knife in butter”



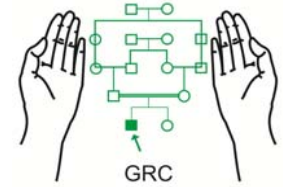
Sampling



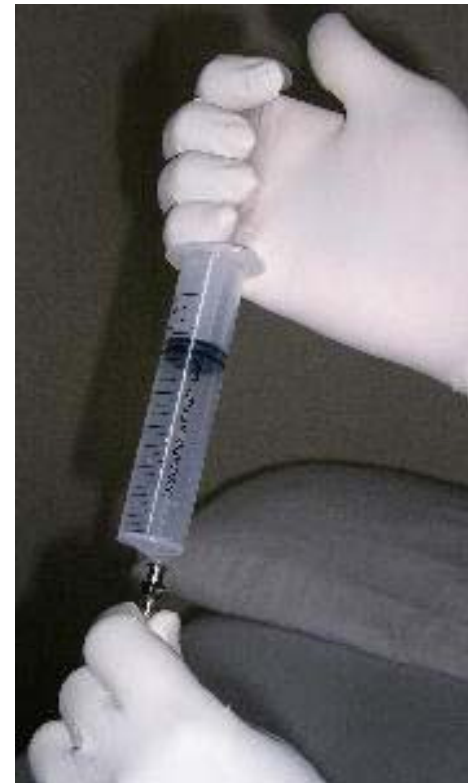- Introduce the aspiration needle with attached 30 ml syringe
- Lack of resistance for tip of the inner needle indicates the needle is in placenta and not uterine wall

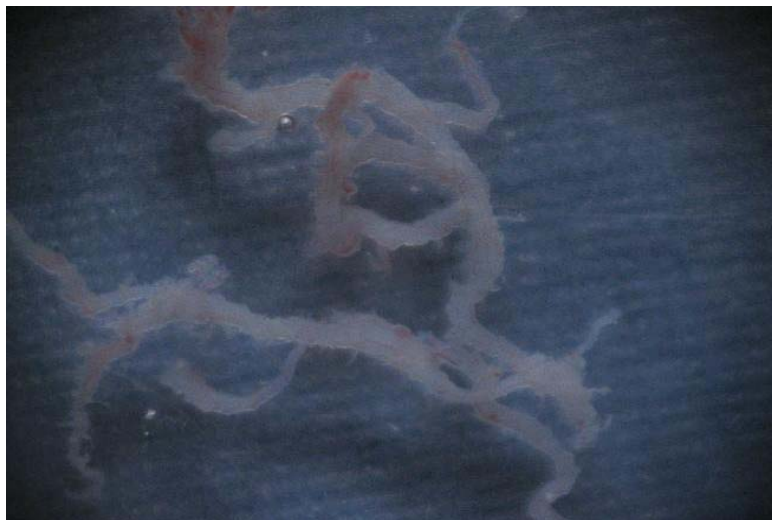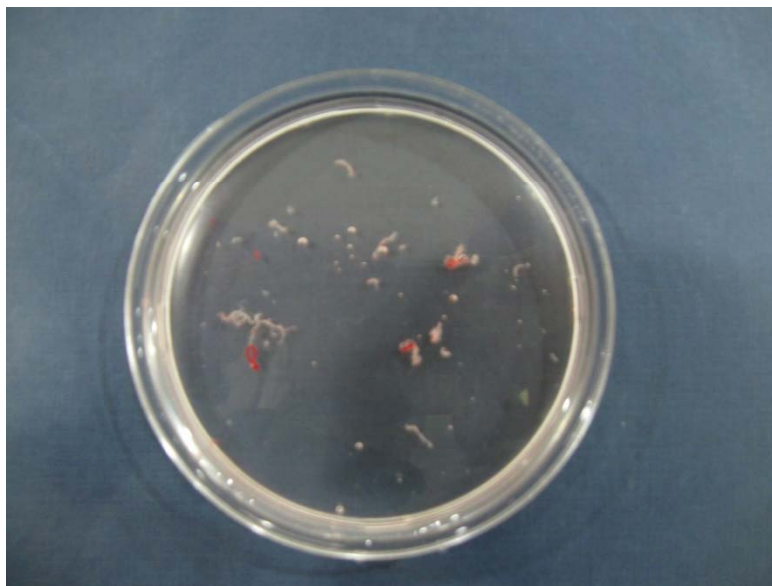
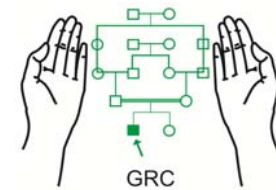


Sampling

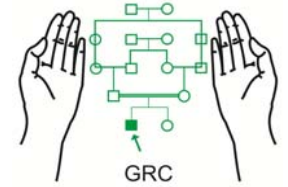


- Apply suction and lock the plunger of the syringe with four fingers
- Jiggle the syringe and the needle to and fro a few times
- Take out the aspiration needle and transfer the sample to saline in sterile Patri dish
- Remove the outer needle and seal the puncture mark



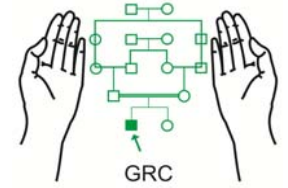


Sampling

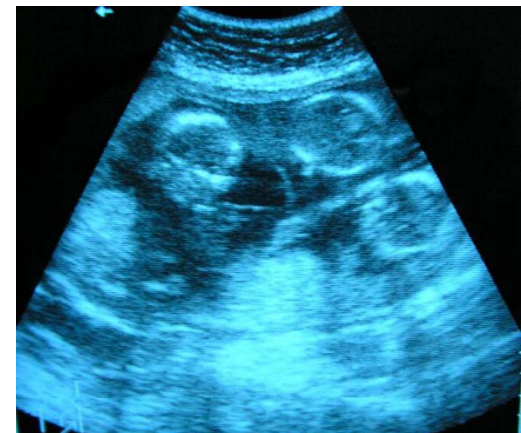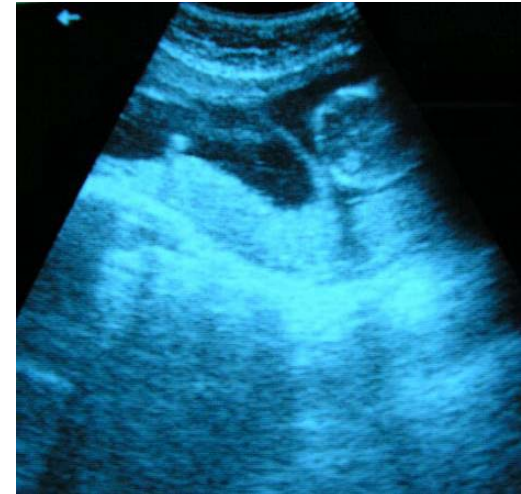


- Post aspiration USG scan to see the fetal well being and formation of placental haematoma or separation
- Patients may be allowed to go home 30-60 minutes after the procedure
- Advise:
 - Bed rest for 24 hours
 - Mild analgesics for pain relief
 - No prophylactic antibiotics

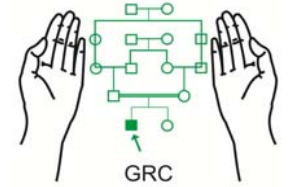
Sampling in Twins



- Monozygotic:
 - one sample?
- Di-zygotic:
 - two samples
- More than two fetuses
- Name the twins

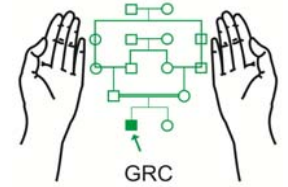


Problems



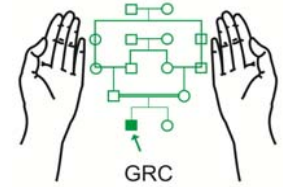
- Sampling in very obese patients
 - Since subcutaneous fat is a poor conductor of ultrasound
 - Delay sampling till 13-14 weeks
- Previous C-section scars
- Fibroids
- Blood tap from the needle

Complications



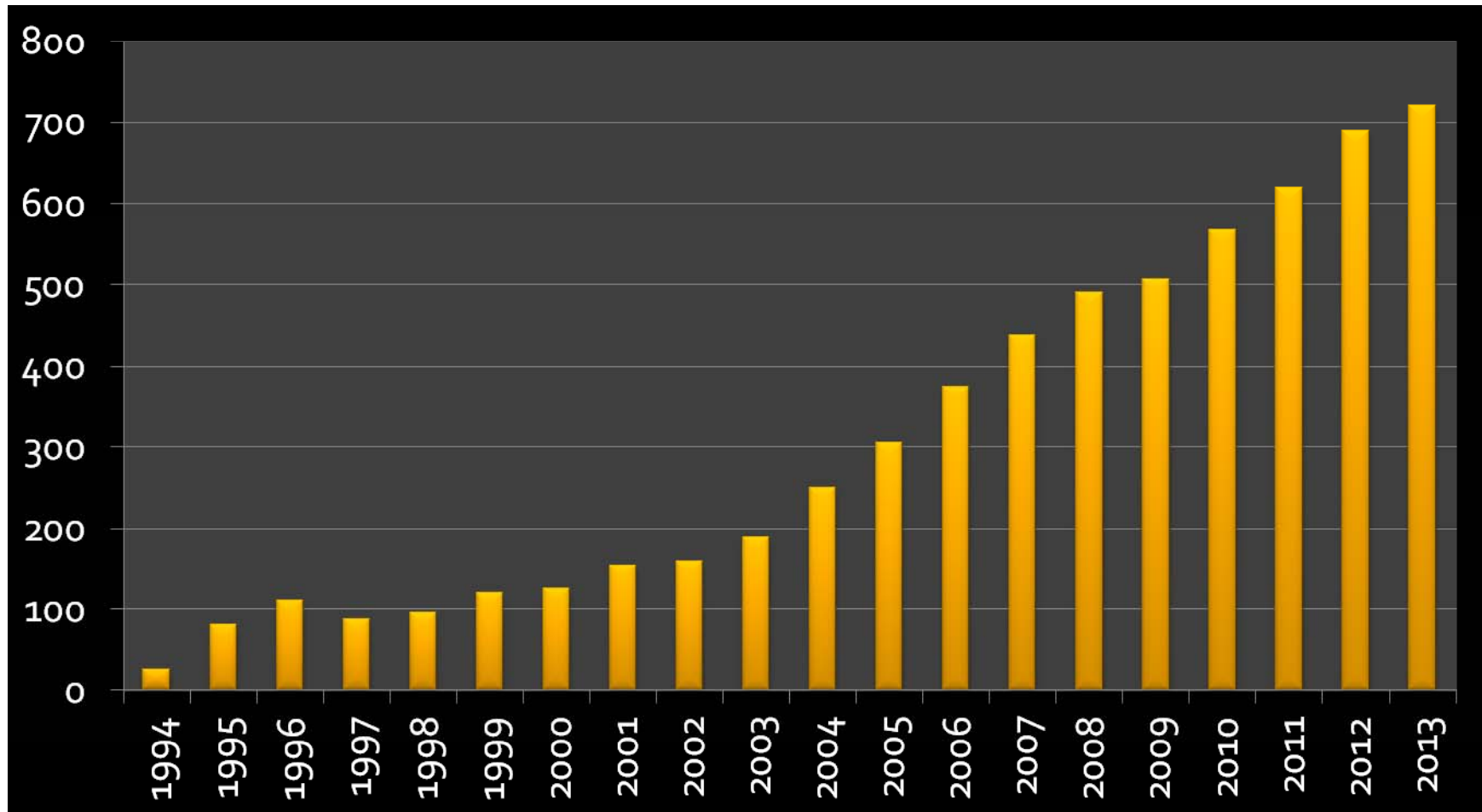
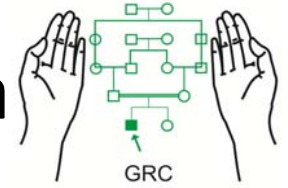
- Uterine cramps
- Dizziness or fainting
- Placental separation and localized haematoma
- Infection
- Miscarriage (1-2%)
- CVS is safe for the fetus
- Limb reduction defects
- Premature labour

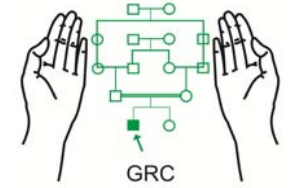
Follow-up



- Keep under observation for 30 to 60 minutes
- Restrict movements like climbing stairs etc.
- Bed rest may be advised for those who develop placental haematoma
- Avoid traveling especially on a bumpy road
- Mild analgesics
- Anti-D prophylaxis (250 μ g) when required

Annual Workload PND for Thalassaemia (AFIP/GRC Rawalpindi)





New Developments

- Fetal cells in maternal blood
- Fetal DNA in maternal blood
- Pre-implantation diagnosis